

CLINICAL CASE

MEGAN RANSLEY, SALES AREA MANAGER,
PHYSIOTHERAPIST, NEW ZEALAND

Actively assisting in healing a pressure injury with the Vicair Active O2

Background

Mr. R has been in a wheelchair for many years, this due to an accident that caused a spinal injury. At 26 years old he became quadriplegic at C6 level. He is a very capable manual wheelchair user and is fully independent in his life. He even runs his own business with great success.

He has always used a gel-based cushion in his wheelchair. It was given to him by the spinal unit, where a fear of pressure injuries was clearly expressed. Whilst Mr. R admits it has been annoying to massage the gel forward every day and the fact that the cushion is relatively heavy, he always considered himself to be 'a Jay man'.

Like many of his friends that are in a similar position, he could not imagine moving from his cushion, he trusted it and it has done the job for many years. His biggest fear was that a pressure injury might appear if he switched cushions.

The problem

Mr. R has recently developed a red area on his bottom that is not going away. He is getting older and his shoulders are less able to push. Older age also brought along other health issues regarding his kidney function and bowel programme. He had spent some time in hospitals and the red area most likely arose from those inpatient stays and a greater amount of passive sitting during that time (whereas he usually moves about a lot in his chair).

His occupational therapist wanted to investigate cushions which could provide robust postural support but would be light weight, easier to maintain and provide the best pressure care.

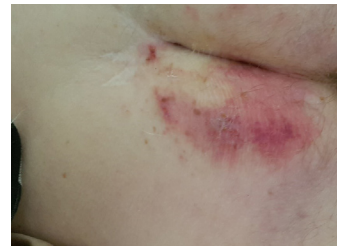
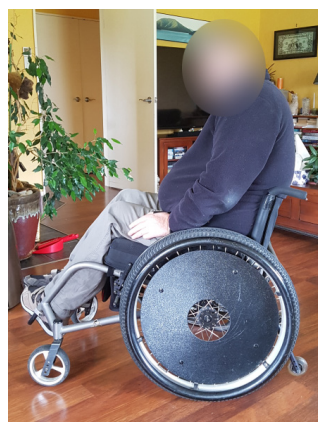
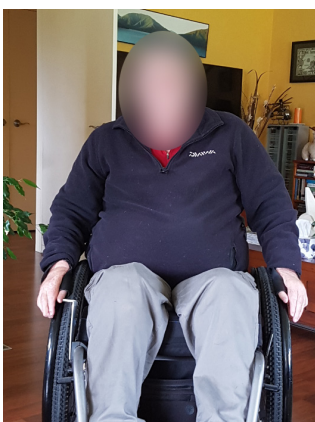Figure 1: Red area at the start of the trial

Implementing Vicair into the seating system

His OT proposed the Vicair Active O2 (9cm high) and Mr. R was reluctant, but since it was only getting worse he agreed to give it a try. The idea was that the Active O2 would assist in healing his wound and if wanted he could always return to his Jay cushion once the wound was healed. Due to the open weave of the Active O2, it was expected that it would provide a lower temperature to help manage the microclimate of his wound that in turn could speed up the healing. An added bonus was the light weight nature of the cushion of which his shoulders would benefit.



His first impression of the cushion was very positive, he felt great stability and that he was positioned more upright than on his Jay. He instantly experienced that he was in a better position to push and that it was also easier to do so. His posture is not yet 'ideal' but to Mr. R it's the function and the protection that really matters.

Figure 2 & 3: Position on the Active O2

Conclusion

A week into the trial Mr. R provided us with the following summary:

"The Vicair seating trial has gone extremely well showing a marked improvement over my current Jay Active. Of particular note is a fading of the dark patch and general skin colour improvement over a relatively short period of around 10 days (see attached comparison photos).

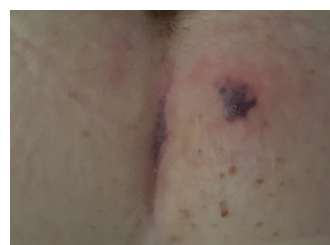

Figure 4: Red area in July 2018 (approximately 10 days after the start of the trial)

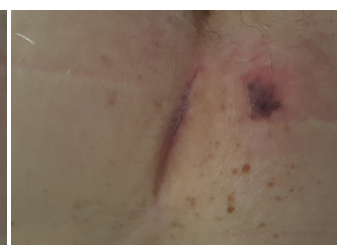

Figure 5: Red area in August 2018

Prior to this the dark patch has remained largely static in size and colour for some months sitting on the Jay Active. The only seating change has been the Vicair I would therefore assume its responsible for the improvement."

Following this, mr. R went into surgery for a Gall Bladder removal after which he once again gave us his comments, it had now been two months since he swapped to the Vicair cushion:

"Vicair cushion continues to impress, being a little more immobile (pressure relief wise) this last week has seen my butt stay at worst status quo but actually we think continuing to improve.

Given I was up and about the day after surgery I was feeling a bit fragile and unable to perform normal pressure relief regime. The Vicair appears to have given the needed protection even though my movements been greatly reduced...I'm extremely happy as you can imagine, attached pics show botty day before surgery and last night!"

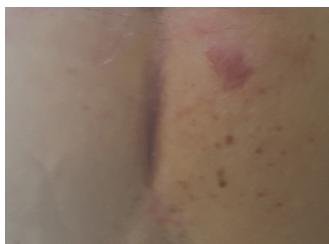

Figure 6: Red area in September 2018

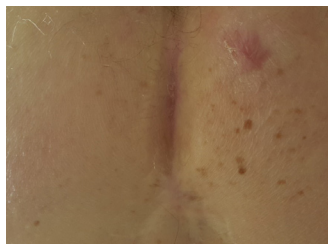


Figure 7: Red area in October 2018

The wound continues to improve, mr. R is delighted with the Active O2 (9 cm) and he now very much considers himself 'a Vicair man'.

**- MEGAN RANSLEY, SALES AREA MANAGER,
PHYSIOTHERAPIST, NEW ZEALAND**